

## English Translation

# Liposuction of Lipedema to Prevent Later Joint Complications

*Josef Stutz, Schwarzenbach am Wald*



Josef Stutz

### Summary

Lipedema is a symmetric fat disorder in women which affects their legs and arms.

Abnormal fat accumulations at the proximal inner thigh cause an abduction of the leg axis which leads to a change in gait, and to an unnatural physiological strain on the leg joints (knock knee).

Using liposuction, this abnormal fat can be reduced, and the leg axis and gait can be corrected.

Key words: lipedema, leg axis, knock-knee, arthrosis.

Lipedema is a symmetrical fat-distribution disease, usually presenting in the legs, less often in the arms. It primarily affects women. This subcutaneous fat tissue increases over time; however, the rate of progression occurs in an unpredictable manner. The physical change is usually noticed by affected patients at the end of puberty as a disproportion between the upper and lower halves of their bodies. Since the disease often runs in families, there is likely a genetic component; since it affects primarily women, there are likely hormonal causes, as well.

Lipedema typically causes a symmetrical growth of fat tissue in the legs, from the iliac crest to the ankles, and in the arms, from the shoulder to the wrist. The feet and hands, however, are always spared from increased fat tissue.

In later stages, the patients are prone to develop orthostatic edema, especially during hot weather and at the end of the day. Additionally, there is a noticeable tendency of affected areas to bruise even after only minor trauma, as well as have increased pain to the touch (1, 4, 13). There is no direct correlation between the extent of the increased abnormal fat tissue and the degree of discomfort.

Due to dynamic insufficiency of the lymphatic drainage in the extremities, lipedema can progress into a lymphostatic edema, referred to as lipo-lymphedema. The unbalanced state of afflux to and

drainage from the limbs leads to a chronic failure of the lymphogenic transport capacity; after about 15-20 years, fibrosis of the cutis and lymphedema with liposclerosis develop as an expression of a chronic final condition, resistant to therapy (2, 11).

There is no reliable epidemiological data regarding the frequency of lipedema, although the literature refers to a prevalence of 10-15%. Lipedema is not a specific form of obesity, since in obese patients, the increase of fat tissue is distributed over the entire body.

### Diagnosis

In addition to the physician taking a thorough medical and family history, the disease is diagnosed by clinical examination. Noting the locations of fat distribution is most important. A large difference in diameter between a slender upper body and bulky buttocks, legs and arms, with slender hands and feet is characteristic. By palpation, noting consistency and thickness, it is possible to establish the border between the disordered adipose tissue of lipedema and healthy, physiologically normal fat tissue. In addition, the surface of the skin of the affected areas feels cold to the examiner's touch. A significant paradox can be found in a comparative pinch test: the outside of the thigh is typically more painful to the touch than the inner thigh. Also, if the back of the upper arm and the fat at the edge of the stomach are

palpated at the same time, the patient reports increased pain in their arm.

## Imaging examinations

Besides CT (12), an MRI can also help to determine the location as well as the extent of the lipedemic fat distribution. Sonography has proved successful to depict the subcutaneous fat tissue (5). The thickness layer and increased echogenicity of the lipedema fat tissue allow it to be differentiated from normal subcutaneous fat. In addition, compression sonography can help to evaluate the remaining compressibility to determine the stage of the disease, and can enable the clinician to judge the degree of pain. Furthermore, to clarify possible coexisting lymphedema, an indirect lymphangiography can be used, as well as a functional lymphoscintigraphy to evaluate the lymphatic drainage.

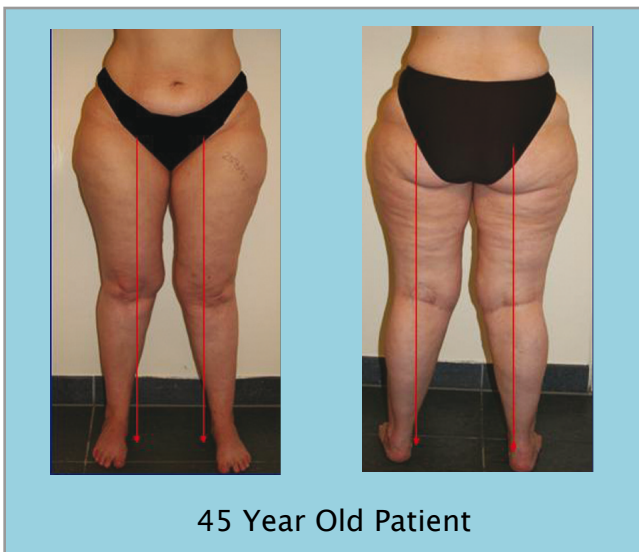

Fig. 1: Leg axes misalignment in a lipedema patient

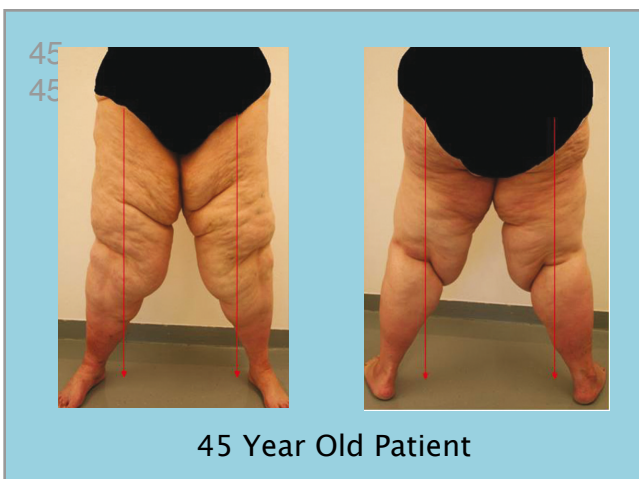
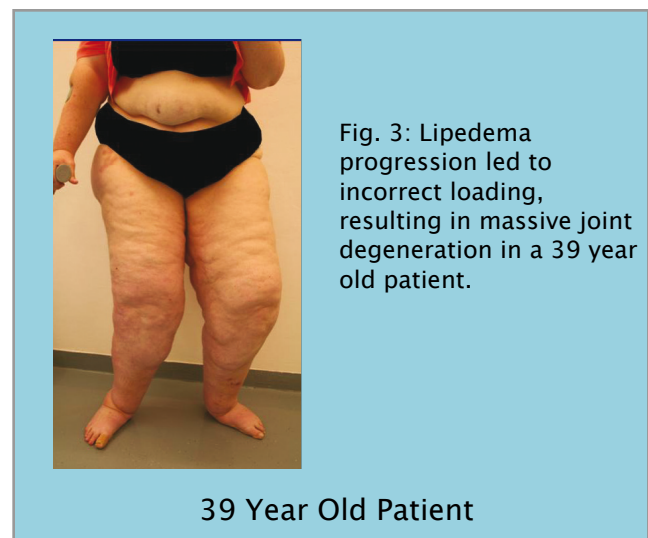


Fig. 2: Incorrect leg axis loading caused by inner thigh fat of lipedema patient.

## Joint involvement

The abnormal accumulations of fat on the legs, especially those on the proximal inside of the thighs, cause affected patients develop a characteristic gait pattern (14). To avoid chafing of the skin, especially in the warmer months, patients tend to abduct their legs while walking, resulting in their being held in an upside-down V-position. These changes can manifest long before the diagnosis of lipedema is made. The patients only notice the increase in circumference of the legs, and believe that the joint pain they feel is due to the accompanying weight gain. As this fat continues to accumulate, the abduction of the legs becomes wider, and the misaligned joint axes become clinically relevant. The improper stress in abduction causes a valgus deformity in the knee joints, and later a “skew-foot” position of the ankle joint and an apparent varus shift of the hip joint. This pseudo coxa-vara position, caused by the abduction of the legs, causes the typical “duck walk” of lipedema patients. This malposition of the joints occurs even in lipedema patients of normal weight. Knock-knees appear in obese patients as well, but in contrast to the malpositioning caused by lipedema, knock-knees due to obesity are accompanied by a valgus position of the hip joint.



After the diagnosis and the start of conservative treatment, the situation for lipedema patients may be improved temporarily, since compression treatment prevents skin injuries on the insides of the thighs. The gait impediment, however, remains, since the abnormal lipedemic fat that causes the typical abduction of the legs remains, as well. Therefore, reestablishment of the normal physiological leg axis is impossible to achieve even with consistent conservative therapy, including lymphatic drainage and compression treatment. The early joint alteration

often leads to repeated mobility impairments and, in some cases, to early disablement (sometimes before age 30), despite conservative treatment. To make matters more complicated, many lipedema patients have developed eating disorders due to years of effort to reduce the size of their legs through exercise and diets. A metabolism that is accustomed to a low-calorie diet, complicated by the inability to exercise sufficiently because of joint pain, leads to a cycle of weight gain, further worsening the situation for the joints.

### Confirmation of the misalignment of the joints

While taking a medical history, the clinician should inquire about manifested joint pain. Are the soles of the shoes worn off unevenly, especially on the medial side of the foot? Has the patient repeatedly been reprimanded in her youth to walk “correctly,” or was her “unusual” gait alluded to in physical education class in school? Was she unable to participate in exercise due to leg pain?

In addition, a clinical examination is performed. Often, an abduction of the lower legs is displayed in a relaxed standing position as well as while walking. The distance between the inside of the ankles is demonstrably larger than the distance between the inside of the knees, and is much bigger than the distance between the proximal insides of the thighs which, in advanced lipedema patients, are always touching. The patient is asked to adduct the ankles; to achieve this, she must rotate her knees inward, since the accumulated fat on her inner thighs prevents a normal adduction of the ankles.

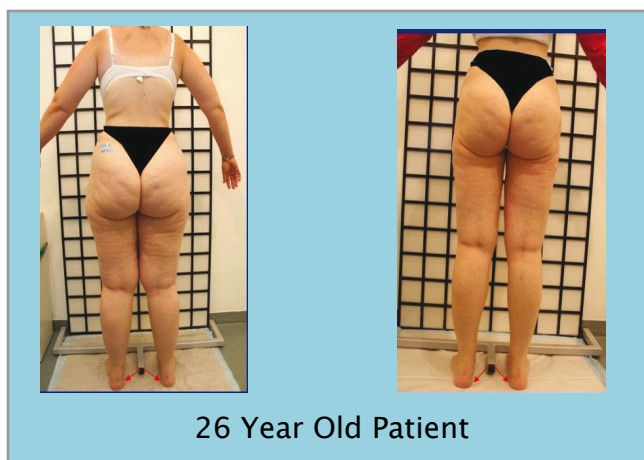

Fig. 4a: Inner thigh lipedema fat causes internal rotation of the leg axes.

Fig. 4b: Six months after WAL liposuction of medial lipedema fat, the leg axes are corrected.

In the early stages, joints usually have a normal range of motion; however, tenderness or pain upon even gentle palpation can often be appreciated above the lateral knee joint space.

If the joint problems have been present for a longer period of time, patients often have previous orthopedic examinations and/or x-rays available. Usually, there are no radiographically visible changes, as generally, a knock-knee position is not depicted in an x-ray because it requires specific, long shots. These involve a high exposure to x-rays, and these views cannot be performed in many imaging centers.

Because of these limitations, the author (in collaboration with orthopedic colleagues) had been searching for an x-ray free and reproducible examination, and decided on a podometric 3D gait analysis. By way of a radio-controlled in-shoe recorder, using a special pressure-sensor sole, the pressure zones underneath the foot can be precisely measured. This video controlled gait analysis is much more exact than the traditional angle measurement, and can be reliably repeated and reproduced using standardized parameters.

These examinations show a pathologically increased pressure on the medial edge of the foot in the majority of lipedema patients. Therefore, there are detectable characteristic changes regarding the pressure zones of the foot in lipedema patients, despite the compensating “skew-foot” movements of the ankle.

Long-term studies were designed to ascertain if there was a normalization of the distribution of pressure on the feet of lipedema patients after the surgical removal of the inner thigh lipedema fat.

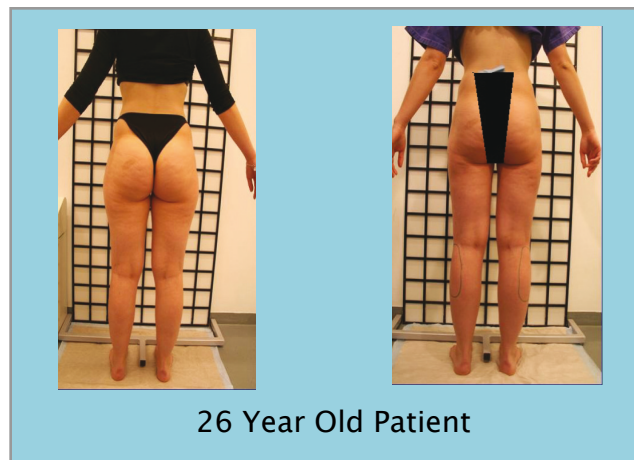


Fig. 5a: Before WAL liposuction

Fig. 5b: Six months after WAL liposuction

## Treatment

Because of the pathophysiology of lipedema, exercise and diets do not reduce the fat mass in the legs. Conservative therapy, if the therapeutic regimen is consistently applied, can contribute to reducing the edema and the discomfort from strain and the pain of pressure. However, conservative therapy understandably has no effect on the localized increase in lipedema fatty tissue.

Since the late 1990s, lipedema has been treated surgically (7) – initially, against massive resistance of lymph physicians and therapists. This original resistance was legitimate, since lipedema was regarded solely as a cosmetic-aesthetic dysfunction, and the results of liposuction using the dry suction methods of that time ranged from disappointing to disastrous. The crisscross technique used in dry liposuction, which was reasonable in aesthetic surgery, ended up destroying numerous lymph vessels in the lipedema patient, which inevitably lead to a post-surgical lymphedema. Anatomical studies have concluded that lymph vessels are rather robust against sheering powers in a longitudinal direction, but can be easily damaged in a transversal axis (3). This led to the insight to use suction longitudinally, in the direction of the lymph axis only. Later, immunehistological examinations were performed to prove more precisely that, with appropriate technique, there was no damage to the lymphatic structures (8, 10). Only suction using tumescent local anesthesia creates the necessary environment in the fat tissue to enable a gentle removal of the diseased fat cells.

Since this early research, numerous successful liposuctions have been performed on lipedema patients.

These encouraging results have been backed up by studies demonstrating an improvement of the quality of life and a reduction of pain (even up to the point of no pain), and a significant reduction in the tendency to develop edema was proven, as well (9).

## Conclusion

Even if the lipedema patient in the early stages of the disease only suffers a slight disproportion between her upper and lower body, lipedema is still very debilitating for her, due to daily insults and dirty looks from other people; the knowledge of potential progression to later complications such as bilateral lymphedema is even more devastating psychologically.

From the author's more than ten years' experience of treating lipedema surgically with liposuction, osteoarthritis of the large leg joints represents the most severe orthopedic complication of lipedema. This often requires one or more total joint replacements, which are performed without treating the actual cause of the malpositioning of the leg axis.

Liposuction of lipedema is the only treatment that can remove the mechanical impediment to the normal gait - namely, the abnormal lipedema fat accumulation on the proximal inner thigh - therefore, liposuction works to prevent early joint deterioration from osteoarthritis of the knee and ankle. In addition, it corrects the characteristic abnormal gait found in lipedema. The frequently used orthopedic measures are appropriate to relieve patients of pain for a certain time span; however, even joint replacement surgeries are not ultimately curative in the lipedema patient, since they neither remove the mechanical gait impediment, nor correct the resulting malpositioning of the leg axis.

This finding supports viewing lipedema as the cause of serious orthopedic disease, and consequently, necessitates explaining to lipedema patients early on that surgical removal of the abnormal fat should be viewed as necessary preventive therapy. Later complications that significantly affect the patients' mobility can be avoided only by surgically removing the abnormal lipedema fat on the legs.

Besides the significant increase in quality of life for the patients (6), removal of lipedema fat through liposuction will result in a considerable reduction in costs to the health care system. Not only will patients need less frequent lymphatic drainage after liposuction, but the costs of orthopedic intervention, up to and including joint replacement, can be avoided, as well.

Liposuction of lipedema has been demonstrated to correct of the malpositioning of the leg axis and the gait, and in addition, to improve the patients' quality of life.

## Citations:

1. Allen EU, Hines EA. Lipedema of the legs: A syndrome characterized by fat legs and orthostatic edema. *Proc Staff Mayo Clin* 1940; 15:184-187.
2. Földi M, Földi E, Kubik Sr. *Lehrbuch der Lymphologie*. Gustav Fischer, Stuttgart - New York 2005.

3. Frick A, Hoffmann JN, Baumeister RGH et al. Liposuction technique and lymphatic lesions in lower legs: Anatomic study to reduce risks. *Plast Reconstr Surg* 1999; 103:1868–1873.
4. Herpertz U. Ödeme und Lymphdrainage. Diagnose und Therapie von Ödemkrankheiten. Schattauer, Stuttgart 2003.
5. Marshall M. Differentialdiagnostische Abklärung des Lymph-, Lip- und Phlebödems mittels hochauflösender (Duplex-) Sonographie. *Ultraschall Klin Praxis* 1996; 10:130–137.
6. Meier-Vollrath I, Schneider S, Schmeller W. Lipödem: Verbesserte Lebensqualität durch Therapiekombination. *Dtsch Arztebl* 2005; 102: A1061–1067 (Heft 15).
7. Sattler G, Hasche E, Rapprich S et al. Neue operative Behandlungsmöglichkeiten bei benignen Fettgewebskrankungen. *Z Hautkr* 1997; 72: 579–582.
8. Schmeller W, Tronnier M, Kaiserling E. Lymphgefäßschädigung durch Liposuktion? Eine immunhistologische Untersuchung *Lymph Forsch* 2006; 9: 81–85.
9. Schmeller W, Meier-Vollrath I. Erfolgreiche operative Therapie des Lipödems mittels Liposuktion. *Phlebologie* 2004; 33:23–29.
10. Stutz JJ, Krahl D. Water jet-assisted liposuction for patients with lipoedema: histologic and immunohistologic analysis of the aspirates of 30 lipoedema patients. *Aesth Plast Surg* 2009; 33: 153–162.
11. Tiedjien Ku, Heimann Kd, Tiedjien U et al. Indirect xero-Lymphography in Lymphedema, Lipedema and venous insufficiency. Raymond-Martin Beau P, Prescott R, Zummo M (eds). *Phlebologie* 92. Paris John Libbey Eurotext 1992: 396–398.
12. Vaughan BF. CT of swollen legs. *Clin Radiology* 1990; 41:24–30.
13. Wienert V, Leeman S. Das Lipödem. *Hautarzt* 1991; 42:484–486.
14. Wienert V et al. DGP-Leitlinie Lipödem. *Phlebologie* 2009; 38:164–167.

### Address for correspondence:

Dr. med. Josef Stutz  
Thiemitztalstraße 6  
95131 Schwarzenbach am Wald  
Germany  
E-Mail: [stutz.dr@t-online.de](mailto:stutz.dr@t-online.de)

### The original article appeared as:

Liposuktion beim Lipödem zur Verhinderung von Gelenkspätkomplikationen  
*Vasomed* Volume 23 (January 2011)  
ISSN: 0942-1181  
Published by Viavital Verlag GmbH  
Belfort Road 9  
50668 Cologne  
Germany